

Sameena Choudhry


Specialist Endodontist

GDC No. 78027

Education/Qualifications

MClinDent MEndo RCSEd (Endodontic
Speciality) Kings College London

DRDP (Diploma in Advanced Restorative Dentistry) Eastman Dental Institute
MFDS Royal College of Surgeons of Edinburgh
BDS Bristol



About Sameena

I qualified at Bristol Dental School in 2000 and spent the following few years in the Southwest gaining experience first in hospital and then in practice. I have undertaken various postgraduate courses in implants, cosmetic dentistry and advanced restorative dentistry at the Eastman Dental Institute, always working to improve professionally, providing dentistry of the highest standard. This led to an interest in endodontics (root canal treatment) and so I completed the four-year specialist-training programme at King's College London.

My work is limited to endodontics because it allows me to focus on this aspect of dentistry and provide root canal fillings to the highest standard. I work in various private practices in Essex and Suffolk as well as being a postgraduate teacher at Kings College. I use a dental microscope as well as other specialist equipment and materials which help make the treatment efficient. My aim is to provide root canal treatment in a comfortable and calm environment by paying attention to detail and doing the little things that help you to feel relaxed.

In my spare time I try to keep fit! I meditate daily and am a qualified yoga teacher. I enjoy most sports, in particular cricket and tennis. I love to cook and am an avid reader. I love travelling and enjoy learning about the varied cultures and trying the cuisines!

Testimonials

"Thank you for the root canal work over the last two weeks – wonderful job.

Today the anaesthetic wore off an hour after I left your surgery – absolutely no pain or discomfort. Amazing work whilst in the chair – well done!" Graham Showell

"Just a quick note to say Thank you so much for your care and attention when you did my root canal filling.

I am pleased to be able to report after the local anaesthetic I felt no pain at all and I have not had any pain since the aesthetic wore off later that day. I am sure this is all due to your skill and expertise so thank you very much indeed." Andrew Cornish

"You very skilfully treated my tooth with canal root treatment, and I wish to thank you Sameena both for your patience and kind consideration.

You are a credit to your Profession.

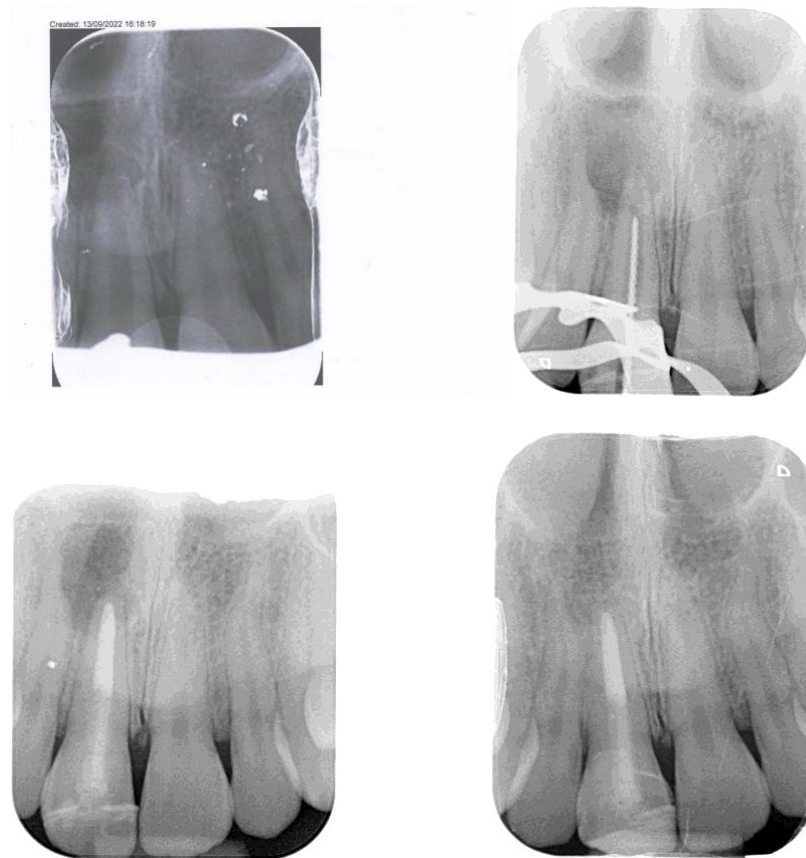
With many thanks." Cynthia Cook

"It is easy to refer to Sameena. The endodontic work is to a high standard. Great communication and good feedback from patients." Dr Sarah Waddington

Cases: I have a few cases below. I often carry out treatment in 2 stages, this allows time for symptoms to resolve and the medication to work.

Case 1

DH: Age 12. Trauma at age 7, fractured tooth. Age 9/10 repeat infections, given antibiotics
Apologies for the poor pre-operative image, print out sent by the dentist. I did not want to expose the patient to unnecessary radiation

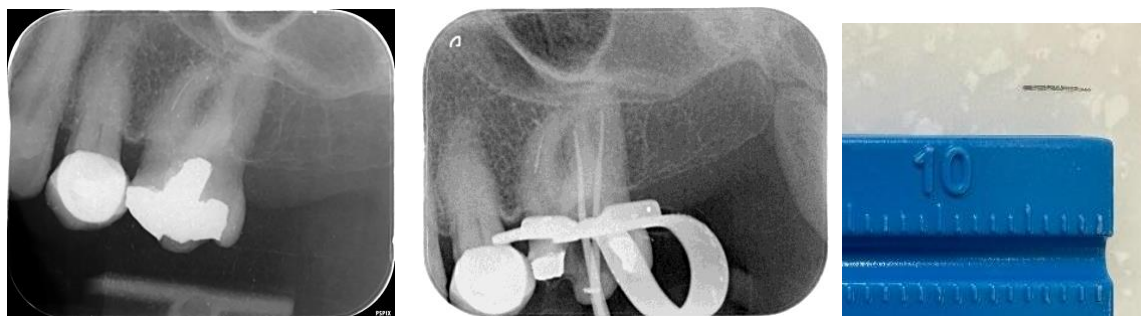


Visit 1: Tooth dressed; pain and swelling resolved
Visit 2: Bio-ceramic apically, fiber reinforced resin

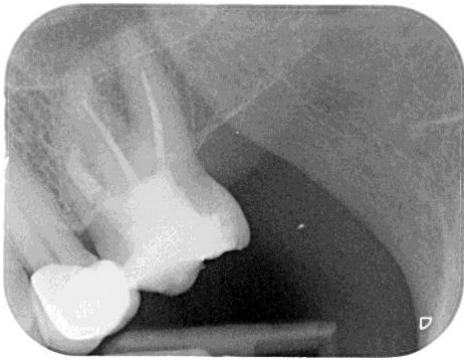
12-month post-treatment: Healed

Case 2

LS: pain upper left, separated file mesial root



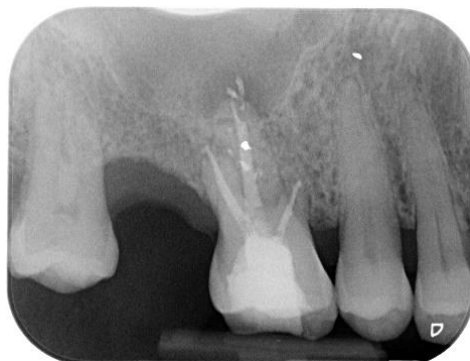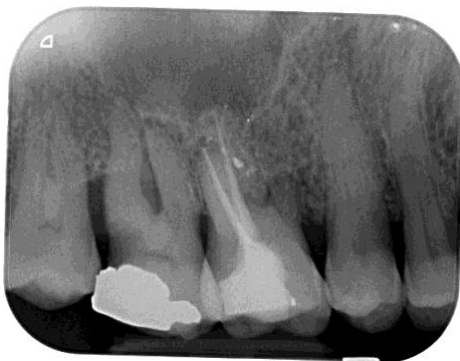Visit 1: File removed with ultrasonics. Sclerosed roots, tooth dressed and wait for symptoms to resolve



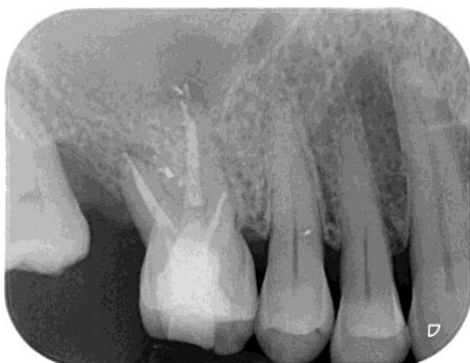Visit 2: Symptoms resolved; tooth filled with fibre reinforced composite resin

Case 3

NK: Pain and swelling buccal to tooth 16. Resorption mesial root. Tooth 17 sub-gingival caries and bone loss.



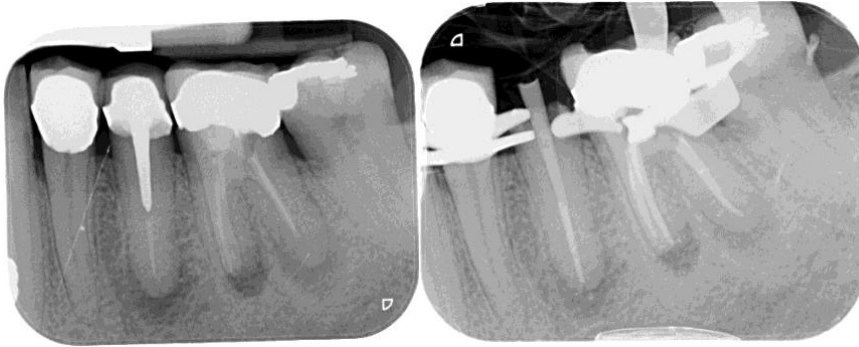Visit 1: Tooth 17 to be removed and tooth 16 dressed; symptoms resolved



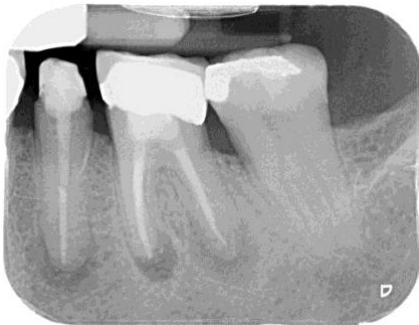6-month post treatment: healing clinically and radiographically

Case 4

LH: pain and swelling LLQ, antibiotics helped, now tender on chewing



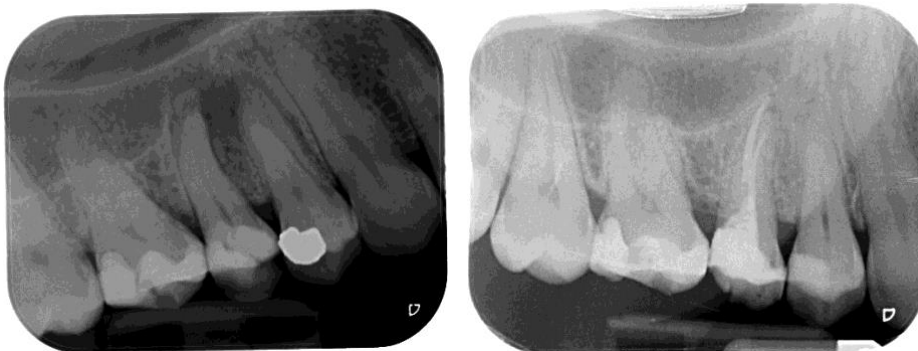Visit 1: post removed twitch ultrasonics and previous root filling removed, following preparation and irrigation, medication placed into root canals for both teeth



Visit 2: symptoms resolved. Root filling placed, fibre post in tooth 35. To review apical healing in summer 2024

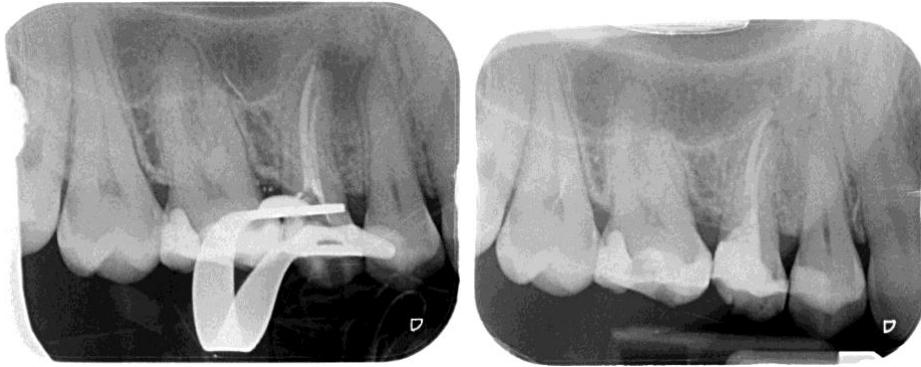
Case 5

JB: pain and swelling URQ, severe root curvature



Visit 1: Prepare, irrigate and dress canals

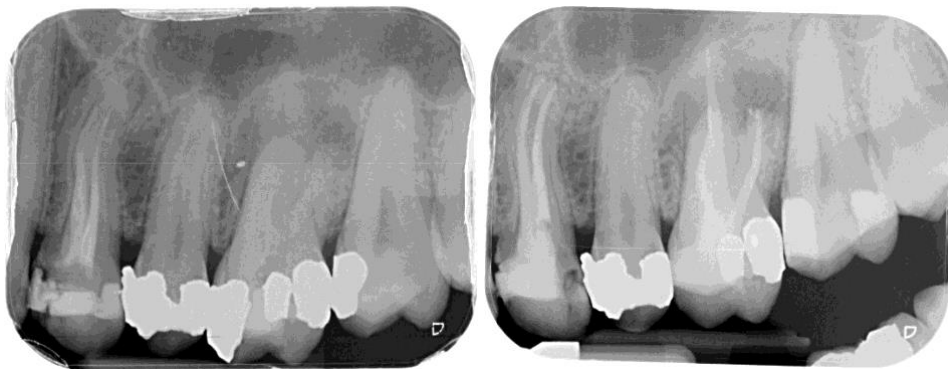Visit 2: symptoms and swelling resolved, root fill and replace amalgam with fibre reinforced composite resin



12-month post-treatment: Full healing

Case 6

JT: Pain and swelling ULQ



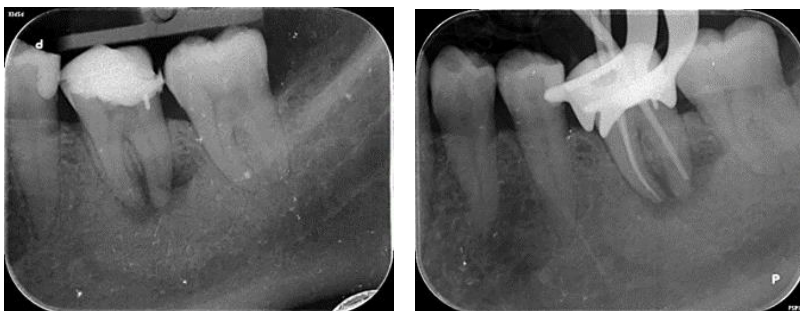
Visit 1: remove infection and previous root filling, irrigate and medicate

Visit 2: symptoms resolved, fill roots with GP and fibre reinforced composite in the access

Review 12 months

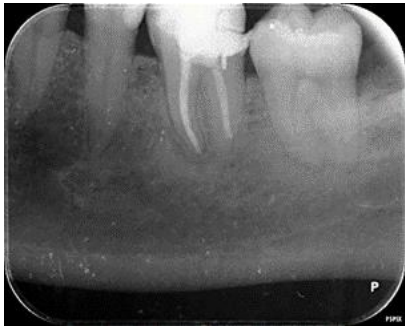Case 7

BC: Pain and swelling LLQ, heavily restored tooth, needs crown



Visit 1: Prepare and dress canals, swelling resolved

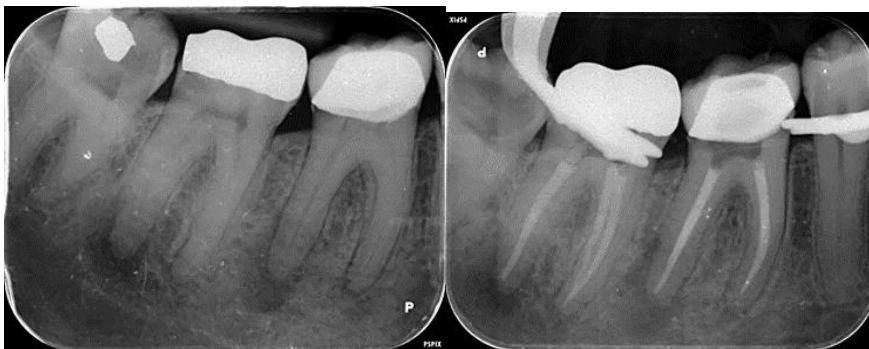Visit 2: root canal filling



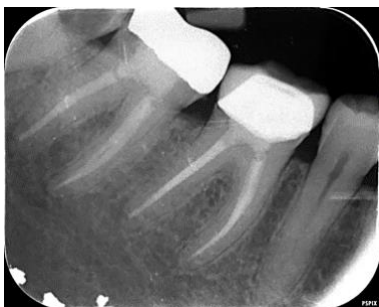6-month review as prefer to crown sooner due to size of restoration, healing occurring

Case 8

TG: pain and swelling lower right



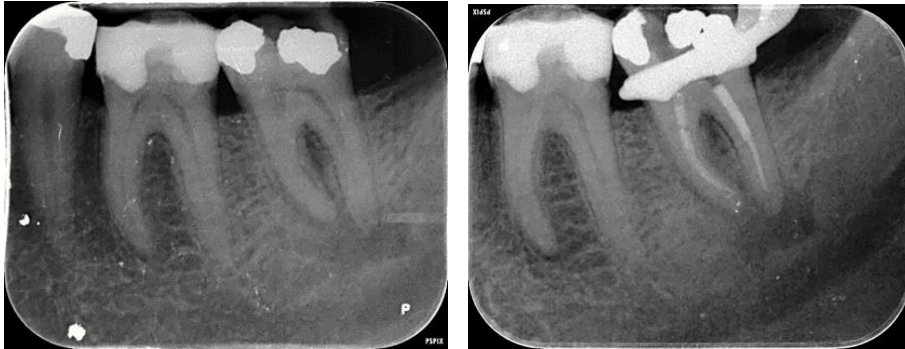Visit 1: access via crowns, prepare and dress, symptoms resolved



12-month review: healing.

Case 9

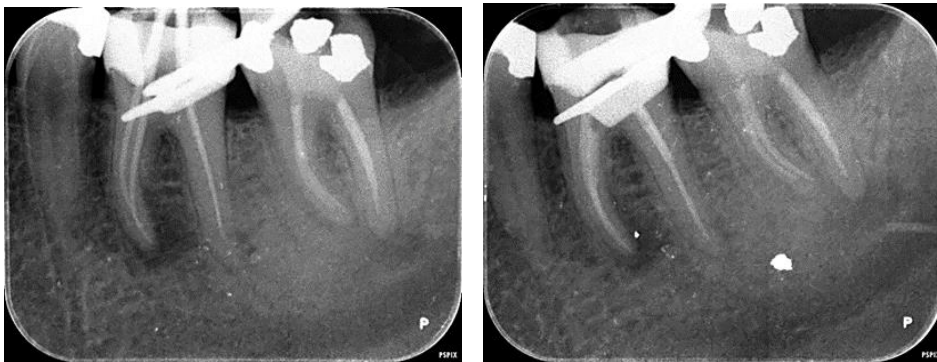SM: pain LLQ, crack in filling



Visit 1: prepare and dress tooth 37. No deep cracks found
warn patient tooth 36 change on mesial root - to keep under review

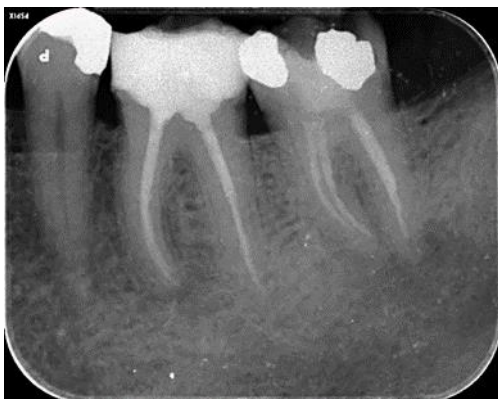Visit 2: root canal filling tooth 37

At 6-month review: apical area tooth 36



Visit 1: root canal preparation and medication

Visit 2: root canal filling



12-month review: apical healing on both teeth